

**BOARD OF MEDICOLEGAL INVESTIGATIONS
OFFICE OF THE CHIEF MEDICAL EXAMINER**

Central Office
921 N.E. 23rd St
Oklahoma City, OK 73105
(405) 239-7141 Phone - (405) 239-2430 Fax

Eastern Division
1115 West 17th Street
Tulsa, Oklahoma 74107
(918) 295-3400 Phone - (918) 585-1549 Fax

OFFICE USE ONLY

Re _____ Co _____

I hereby certify that this is a true and correct copy of the original document. Valid only when copy bears imprint of the office seal.

By _____
Date _____

REPORT OF INVESTIGATION BY MEDICAL EXAMINER

DECEDENT First-Middle-Last Names (Please avoid use of initials) ZONTERIOUS JOHNSON	Age 24	Birth Date 1/15/1997	Race BLACK	Sex M
---	-----------	-------------------------	---------------	----------

HOME ADDRESS - No. - Street, City, State
1712 SW 14TH, LAWTON, OK

EXAMINER NOTIFIED BY - NAME - TITLE (AGENCY, INSTITUTION, OR ADDRESS) BRIANNE HENRY, RN @ COMANCHE COUNTY MEMORIAL	DATE 1/17/2021	TIME 4:41
---	-------------------	--------------

INJURED OR BECAME ILL AT (ADDRESS)	CITY	COUNTY	TYPE OF PREMISES	DATE	TIME
11TH & PARK	LAWTON	COMANCHE	STREET	1/17/2021	3:30
LOCATION OF DEATH COMANCHE COUNTY MEMORIAL HOSPITAL	LAWTON	COMANCHE	HOSPITAL ER	1/17/2021	4:28
BODY VIEWED BY MEDICAL EXAMINER 921 NE 23RD	OKLAHOMA CITY	OKLAHOMA	AUTOPSY LAB	1/19/2021	12:00


TRANSPORTATION INJURY DRIVER PASSENGER PEDESTRIAN

TYPE OF VEHICLE: AUTOMOBILE LIGHT TRUCK HEAVY TRUCK BICYCLE MOTORCYCLE OTHER: _____

DESCRIPTION OF BODY	RIGOR	LIVOR	EXTERNAL OBSERVATION		NOSE	MOUTH	EARS
					BLOOD	OTHER	
EXTERNAL PHYSICAL EXAMINATION	Jaw <input type="checkbox"/> Complete <input checked="" type="checkbox"/>	Color NOT APPAREN	Beard _____ Hair BLACK		<input type="checkbox"/>	<input type="checkbox"/>	<input type="checkbox"/>
	Neck <input type="checkbox"/> Absent <input type="checkbox"/>	Lateral <input type="checkbox"/>	Eyes: Color BROWN Mustache PRESENT		<input type="checkbox"/>	<input type="checkbox"/>	<input type="checkbox"/>
	Arms <input checked="" type="checkbox"/> Passing <input type="checkbox"/>	Posterior <input type="checkbox"/>	Opacities _____				
	Legs <input checked="" type="checkbox"/> Passed <input type="checkbox"/>	Anterior <input type="checkbox"/>	Pupils: R 5 MM L 5 MM				
	Decomposed <input type="checkbox"/>	Regional _____	Body Length 75 INCHES Body Weight 156 LBS.				

Significant observations and injury documentations - (Please use space below)
 MULTIPLE GUNSHOT WOUNDS (3) FROM OFFICER INVOLVED SHOOTING.
 -PERFORATING GUNSHOT WOUND TO THE CHEST (GSW#1)
 -PERFORATING GUNSHOT WOUND TO THE CHEST (GSW#2)
 -PERFORATING GUNSHOT WOUND TO THE RIGHT FOOT (GSW#3)

Probable Cause of Death: MULTIPLE GUNSHOT WOUNDS	Manner of Death: Natural <input type="checkbox"/> Accident <input type="checkbox"/> Suicide <input type="checkbox"/> Homicide <input checked="" type="checkbox"/> Unknown <input type="checkbox"/> Pending <input type="checkbox"/> Not Assigned <input type="checkbox"/>	Case disposition: Autopsy YES Authorized by LEONARDO ROQUERO M.D. Pathologist LEONARDO ROQUERO M.D. Not a medical examiner case <input type="checkbox"/>
	Other significant conditions contributing to death (but not resulting in the underlying cause given)	

MEDICAL EXAMINER: Name, and Address: LEONARDO ROQUERO M.D. 921 NE 23rd Street Oklahoma City, ok 73105	I hereby state that, after receiving notice of the death described herein, I conducted an investigation as to the cause and manner of death, as required by law, and that the facts contained herein regarding such death are true and correct to the best of my knowledge.  Signature of Medical Examiner LEONARDO ROQUERO M.D. Computer generated report	1/17/2021 Date Case Initiated 3/26/2021 Date Case Finalize
--	---	---



Board of Medicolegal Investigations
Office of the Chief Medical Examiner

921 N.E. 23rd St
Oklahoma City, OK 73105
(405) 239-7141 Phone
(405) 239-2430 Fax

CERTIFICATION I hereby certify that this document is a true and correct copy of the original document. Valid only when copy bears imprint of the office seal. By _____ Date _____

REPORT OF AUTOPSY

Decedent ZONTERIOUS JOHNSON	Age 24	Birth Date 1/15/1997	Race BL	Sex M	Case No 2100350
Means OFFICER INVOLVED SHOOTING	ID By VISUAL/TAG	Authority for Autopsy LEONARDO ROQUERO, M.D.			

Present at Autopsy
ASHLEY WELCH (INVESTIGATOR), ESTEFANI LOPEZ (PATHOLOGY ASSISTANT)

FINDINGS

- I. Multiple gunshot wounds (3)
- Perforating gunshot wound to the chest (GSW#1)
 - Perforating gunshot wound to the chest (GSW#2)
 - Perforating gunshot wound to the right foot (GSW#3)

OPINION AND SUMMARY:

It is my opinion that death was caused by multiple gunshot wounds sustained in an officer involved shooting.

There were three (3) gunshot wounds on the body: chest (2) and right foot (1). There was no muzzle impression, soot or gunpowder stippling noted on the skin surrounding any of the wounds. Unless otherwise stated, the wound tracks were described when the body is viewed in the standard anatomical position. The gunshot wounds were arbitrarily numbered for ease of description and do not reflect the sequence of firing.

OPINION AND SUMMARY (cont'd on page 2):

CAUSE OF DEATH: MULTIPLE GUNSHOT WOUNDS

MANNER OF DEATH: HOMICIDE

The facts stated herein are true and correct to the best of my knowledge and belief.

OCME Central Division 1/19/2021 12:00 PM

LEONARDO ROQUERO, M.D. Pathologist

Location of Autopsy

Date and Time of Autopsy

OPINION AND SUMMARY (cont'd):

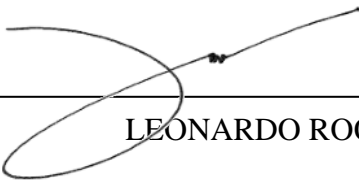
TWO PERFORATING GUNSHOT WOUNDS TO THE CHEST (GSW#1 AND GSW#2):

There were two entrance gunshot wounds on the chest: right of the midline (**GSW#1**) and midline chest (**GSW#2**). The wound track of **GSW#1** proceeded through the skin and subcutaneous soft tissue, right 3rd rib, and upper and middle lobes of the right lung. The wound track of **GSW#2** proceeded through the skin and subcutaneous soft tissue, right 4th rib at the parasternal and middle lobe of the right lung. Both gunshot wounds continued through the posterior chest cavity towards the right 6th and 7th ribs and ended with 2 exit wounds on the right surface of the back. Associated injuries included fractures of the anterior right 3rd and 4th ribs, and posterior right 6th and 7th ribs, perforating injuries of the right lung and bleeding into the right chest cavity. The wound tracks of **GSW#1** and **GSW#2** were from front to back and left to right. There was no bullet or part of bullet recovered from the wound track.

PERFORATING GUNSHOT WOUND TO THE RIGHT FOOT (GSW#3):

There was an entrance gunshot wound on the sole surface of the big toe of the right foot. The wound track proceeded from this injury through the skin and subcutaneous soft tissue, bones, and ended at an exit wound on the middle area of the sole of the right foot. Associated injuries included soft tissue hemorrhage, laceration of the sole surface and fracture of the right foot. The wound track was from front to back and left to right. There was no bullet or part of bullet recovered from the wound track.

March 23, 2021
LRA/kg



LEONARDO ROQUERO, M.D.

EXTERNAL EXAMINATION:

The body was received with the Oklahoma Office of the Chief Medical Examiner identification tag. The body was that of a normally developed and nourished, Black American, male, appearing about the recorded age of 24 years. The body measured 75 inches in length and weighed 156 pounds (BMI = 19.5 kg/m²). Rigor mortis was complete. The red-tan livor mortis was present posteriorly and fixed. The decedent was received from a hospital where his clothes were torn. He was wearing a blood stained white t-shirt, green t-shirt and black hooded jacket with defects; blue boxer shorts and black jeans with defects; black pair of socks and white rubber shoes with the right sock and the blood stained right rubber shoe had defects. There were personal effects also present. The head was normocephalic and the scalp hair was black. The eyes had white sclerae, pale conjunctivae, and brown irides having 5 millimeter dilation of the pupils. The dentition was natural. There was a mustache. No lesions of the oral mucosa were identified. There were no masses discernable in the neck and the larynx was in the midline. The abdomen was flat. The external genitalia were those of a normal adult circumcised male. There were tattoos on the left chest and bilateral upper extremities. There were scars across the upper abdomen, lower back and extremities. Swabs (oral, penile and anal), hair (scalp and pubic hair), fingernail clippings and photographs were obtained.

EVIDENCE OF TREATMENT:

- Endotracheal tube in place
- Blood pressure cuff around the left arm
- Intravascular lines in the left inguinal area
- Right and left chest tubes in place
- Defibrillator and electrocardiograph pads were present

EVIDENCE OF INJURY:

GUNSHOT WOUNDS

There were three (3) gunshot wounds on the body: chest (2) and right foot (1). There was no muzzle impression, soot or gunpowder stippling noted on the skin surrounding any of the wounds. Unless otherwise stated, the wound tracks were described when the body is viewed in the standard anatomical position. The gunshot wounds were arbitrarily numbered for ease of description and do not reflect the sequence of firing.

TWO PERFORATING GUNSHOT WOUNDS TO THE CHEST (GSW#1 AND GSW#2):

The entrance gunshot wound of **GSW#1** was located on the chest, 16 inches below the top of the head and ½ inches right of the anterior midline. There was no muzzle impression, soot or gunpowder stippling noted on the skin surrounding this wound. The wound track of **GSW#1** proceeded from this injury through the skin and subcutaneous soft tissue, right 3rd rib, and upper and middle lobes of the right lung. The entrance gunshot wound of **GSW#2** was located on the midline chest, 18-1/2 inches below the top of the head. There was no muzzle impression, soot or gunpowder stippling noted on the skin surrounding this wound. The wound track of **GSW#2** proceeded from this injury through the skin and subcutaneous soft tissue, right 4th rib at the parasternal and middle lobe of the right lung. **GSW#1** and **GSW#2** continued through the posterior right chest cavity towards the posterior surface of the right 6th rib and posterolateral surface of the right 7th rib and ended with 2 exit wounds on the back as follows: 15 inches below the top of the head and 6-1/2 inches right of the posterior midline and 17 inches below the top of the head and 7 inches right of the posterior midline. Associated injuries included fractures of the anterior right 3rd and 4th ribs, and posterior

EVIDENCE OF INJURY (cont'd):

right 6th and 7th ribs, perforating injuries of the right lung and right hemothorax of at least 1200 milliliter. The wound tracks of **GSW#1** and **GSW#2** were from front to back and left to right when the body is viewed in the standard anatomical position. There was no bullet or part of bullet recovered from the wound track.

PERFORATING GUNSHOT WOUND TO THE RIGHT FOOT (GSW#3):

There was an entrance gunshot wound on the plantar surface of the big toe of the right foot. There was no muzzle impression, soot or gunpowder stippling noted on the skin surrounding this wound. The wound track proceeded from this injury through the skin and subcutaneous soft tissue, cuboid, and calcaneus bones, and ended at an exit wound on the middle area of the plantar surface of the right foot. Associated injuries included soft tissue hemorrhage, laceration of the plantar surface and fractures of the cuboid and calcaneus bones. The wound track was from front to back and left to right when the body is viewed in the standard anatomical position. There was no bullet or part of bullet recovered from the wound track.

INTERNAL EXAMINATION:

ORGAN WEIGHTS (in grams):

Brain:	1367
Heart:	310
Right Lung:	263
Left Lung:	294
Liver:	1550
Spleen:	37
Right Kidney:	105
Left Kidney:	94

An autopsy was performed utilizing the normal thoraco-abdominal and posterior coronal scalp incisions. The pleural and pericardial cavities had smooth serosal surfaces and the viscera were in their normal anatomical positions. The peritoneal cavity had adhesion and the viscera were in their normal anatomical positions. **Except for the above previously described injuries**, the internal systems were as follows:

Head:

No abnormality was noted in the reflected scalp, calvarium, dura, meninges or the base of the skull. The 1367 gm brain was free of neoplastic and other focal lesions, infarcts, and hemorrhages. The cerebral vascular system was unremarkable.

Neck:

No abnormality was noted in the cervical muscles, hyoid bone, laryngeal cartilages, trachea, or the cervical vertebral column.

Cardiovascular System:

The 310 gm heart had a normal configuration with an unremarkable epicardial surface and a moderate amount of epicardial fat. The coronary arteries had no significant atherosclerotic disease. No acute thrombi were present. Both ventricles were of normal size and their walls were of normal thickness. No focal endomyocardial lesions were present. The papillary muscles and chordae tendineae were not thickened, and the heart valves were unremarkable. The aorta had no significant atherosclerosis. The major arteries and great veins showed normal distribution.

Respiratory System:

The larynx and trachea were unremarkable. The right and left lungs weighed 263 gm and 294 gm, respectively. There was congestion in the parenchyma. No pulmonary emboli were identified.

Hepatobiliary System:

The 1550 gm liver had firm dark tan surfaces and an unremarkable parenchymal pattern. The gallbladder and biliary tracts were unremarkable.

Hemolymphatics:

The 37 gm spleen had smooth surfaces and dark purple firm pulp. There was no significant lymphadenopathy.

Alimentary System:

The tongue, esophagus, stomach, small bowel, appendix and colon were unremarkable. The lining of the stomach had an intact and unremarkable rugal pattern. The stomach contained less than 15 milliliter of mucoid fluid.

Pancreas:

The pancreas showed an unremarkable tan lobulated pattern.

Endocrine System:

The thyroid gland had a normal bilobed configuration. The adrenal glands were each unremarkable with golden-yellow cortices.

Genitourinary System:

The right and left kidneys weighed 105 gm and 94 gm, respectively. Each kidney had smooth cortical surfaces, normal cortico-medullary regions and no changes in the calyceal systems, pelves, ureters, or bladder.

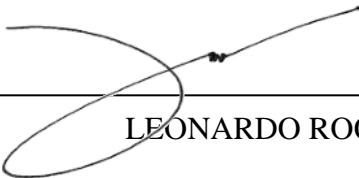
Musculoskeletal System:

Except for the above noted injuries, all the muscles and axial skeleton were free of any significant abnormalities.

RADIOGRAPHS:

Anterior postmortem radiographs together encompassing the head, torso and extremities were taken and findings were included in the evidence of injury.

March 23, 2021
LRA/kg



LEONARDO ROQUERO, M.D.

**BOARD OF MEDICOLEGAL INVESTIGATIONS
OFFICE OF THE CHIEF MEDICAL EXAMINER**

921 N.E. 23rd St
Oklahoma City, OK 73105

REPORT OF LABORATORY ANALYSIS

OFFICE USE ONLY

Re. _____ Co. _____

I hereby certify that this is a true and correct copy of the original document. Valid only when copy bear im-print by the office seal.

By _____

Date _____

ME CASE NUMBER: 2100350

LABORATORY NUMBER: 210368

DECEDENT'S NAME: ZONTERIOUS JOHNSON

DATE RECEIVED: 1/20/2021

MATERIAL SUBMITTED: BLOOD, VITREOUS, URINE, LIVER, BRAIN,
GASTRIC

HOLD STATUS: 5 YEARS

SUBMITTED BY: ESTEFANI LOPEZ INVESTIGATOR

MEDICAL EXAMINER: LEONARDO ROQUERO M.D.

NOTES:

ETHYL ALCOHOL:

Blood: 0.05 g/dL - (Heart)

Vitreous: 0.09 g/dL

Other:

CARBON MONOXIDE

Blood:

TESTS PERFORMED:

ALKALINE DRUG SCREEN - (Heart Blood)

EIA - (Heart Blood) - Amphetamine, Methamphetamine, Fentanyl, Cocaine, Opiates, PCP, Barbiturates, Benzodiazepines
(The EIA panel does not detect Oxycodone, Methadone, or Clonazepam)

RESULTS:

METHAMPHETAMINE
0.09 mcg/mL - (Femoral Blood)

AMPHETAMINE
TRACE - (not confirmed) - (Heart Blood)

03/19/2021

DATE



JESSE KEMP, Ph.D., D-ABFT-FT, Chief Forensic Toxicologist